

Effect of systemic ozone therapy as a biomodulator of tissue regeneration and inflammatory response in rats

Efeito da terapia sistêmica de ozônio como um biomodulador da regeneração tecidual e da resposta inflamatória em ratos

Juliana Rico PIRES^a , Alexandre Melo KARAM^b , Valdir Gouveia GARCIA^c ,
Fernando Salimon RIBEIRO^d , Ana Emilia Farias PONTES^e , Cleverton Roberto de ANDRADE^f ,
Elizangela Cruvinel ZUZA^{g*} 

^aUNIFEB – Centro Universitário da Fundação Educacional de Barretos, Departamento de Odontologia, Barretos, SP, Brasil

^bColégio Regional Bahiano, Salvador, BA, Brasil

^cUNESP – Universidade Estadual Paulista, Faculdade de Odontologia, Departamento de Cirurgia e Clínica Integrada, Araçatuba, SP, Brasil

^dCirurgião-dentista, Governador Valadares, MG, Brasil

^eUFJF – Universidade Federal de Juiz de Fora, Departamento de Odontologia, Governador Valadares, MG, Brasil

^fUNESP – Universidade Estadual Paulista, Faculdade de Odontologia, Departamento de Fisiologia e Patologia, Araraquara, SP, Brasil

^gUFF – Universidade Federal Fluminense, Instituto de Saúde de Nova Friburgo, Programa de Pós-Graduação em Odontologia, Nova Friburgo, RJ, Brasil

How to cite: Pires JR, Karam AM, Garcia VG, Ribeiro FS, Pontes AEF, Andrade CR, et al. Effect of systemic ozone therapy as a biomodulator of tissue regeneration and inflammatory response in rats. Rev Odontol UNESP. 2021;50:e20210046. <https://doi.org/10.1590/1807-2577.04621>

Resumo

Introdução: Dentre os efeitos terapêuticos da ozonioterapia, destacam-se a melhora do metabolismo celular e da oxigenação dos tecidos periféricos. **Objetivo:** avaliar o efeito sistêmico da terapia bio-oxidativa com gás ozônio na cicatrização de feridas. **Material e método:** Lesões teciduais com circunferência de 1,0 cm foram induzidas na pele do dorso de 24 ratos Wistar machos. Os animais foram divididos aleatoriamente em dois grupos: 1) Grupo C (controle; n = 12): com simulação da aplicação de gás ozônio pelo reto e, 2) Grupo O₃ (teste; n = 12): com aplicação de gás ozônio por meio de insuflação retal na concentração de 50 µg / mL. Os animais foram sacrificados com sete e 15 dias, e as amostras foram retiradas, fixadas em formalina e submetidas às análises macroscópica, histológica e histométrica. **Resultado:** Os animais do grupo O₃ apresentaram inflamação mista aos sete dias, que se traduziu em ausência de inflamação aos 15 dias. O grupo C apresentou inflamação aguda no 7º dia, traduzindo-se em inflamação crônica, que aumentou significativamente do 7º para o 15º dia. Os achados mostraram que o grupo O₃ apresentou maior contração da ferida (P <0,05) e maior grau de neovascularização no 7º dia (P <0,05) quando comparado ao grupo C. No 15º dia, ambos os grupos (O₃ e C) apresentaram completa reepitelização, entretanto, o grupo O₃ demonstrou completa regeneração muscular. **Conclusão:** A ozonioterapia sistêmica teve efeito biomodulador, reduzindo as características de inflamação aguda e aumentando a reparação e regeneração tecidual na pele de ratos.

Descritores: Ozônio; cicatrização; inflamação; ratos.

Abstract

Introduction: Among the therapeutic effects of ozone therapy, improvement in cell metabolism and peripheral tissue oxygenation have been highlighted. **Objective:** to evaluate the systemic effect of bio-oxidative therapy with ozone gas on wound healing. **Material and method:** Tissue lesions with a circumference of 1.0 cm were induced in the skin on the back of 24 male Wistar rats. The animals were randomly divided into two groups: 1) Group C (control; n=12): with simulation of the application of ozone gas via the rectum and, 2) Group O₃ (test; n=12): with application of ozone gas by means of rectal insufflation



at a concentration of 50 µg/mL. The animals were euthanized at seven and 15 days, and samples were removed, fixed in formalin, and submitted to macroscopic, histological, and histometric analyses. **Result:** The animals in the O₃ group presented mixed inflammation at seven days, which translated into an absence of inflammation at 15 days. The C group exhibited acute inflammation on the 7th day, translating to chronic inflammation, which significantly increased from the 7th to the 15th day. The findings showed that the O₃ group presented greater wound contraction ($P<0.05$) and a greater degree of neovascularization on the 7th day ($P<0.05$) when compared to group C. On the 15th day, both groups (O₃ and C) showed complete re-epithelialization, however, the O₃ group demonstrated complete muscle regeneration. **Conclusion:** The systemic ozone therapy had a biomodulatory effect, reducing the characteristics of acute inflammation and increasing tissue repair and regeneration in rat skin.

Descriptors: Ozone; wound healing; inflammation; rats.

INTRODUCTION

Ozone therapy is a bio-oxidative therapy based on the use of a gaseous mixture of oxygen and medicinal ozone, and among its therapeutic effects, improvement in metabolism and peripheral tissue oxygenation have been highlighted¹. Its first application in medicine was the use of gaseous ozone to treat post-traumatic gangrene in German soldiers during the First World War². The application of ozone has been recognized as a therapeutic modality in the treatment of ocular, orthopedic, dermatological, pulmonary, renal, and hematological pathologies², and in the treatment of viral³, fungal⁴, and acute and/or chronic bacterial infections⁵.

Ozone therapy has been indicated in cases of wound healing and various dental treatments, such as dental caries, oral lichen planus, gingivitis/periodontitis, halitosis, osteonecrosis of the jaw, post-surgical pain, treatment of root canals, dentinal hypersensitivity, disorders of the temporomandibular joint, and tooth whitening⁶. Ozone treatment has also been shown to be efficient in association with surgical procedures in patients who use bisphosphonates, in order to prevent and/or avoid the onset of osteonecrosis and to repair bone defects⁷.

Some studies have also shown that ozone therapy is biocompatible, acting on metabolic processes mediated by oxygen, calcium, phosphorus, and iron⁸, in addition to having germicidal, analgesic, and reparative action⁷. Ozone treatment has demonstrated restorative properties⁹, showing increased expression of mediators such as platelet-derived growth factor (PDGF), transforming growth factor beta (TGF-β), and vascular growth factor (VGF).

Studies performed *in vitro* through exposure of epithelial cell cultures demonstrated that short and repeated exposures to oxidative stress with ozone improve cell plasticity, through the induction of anti-apoptotic pathways, as a cellular adaptive response to the stress suffered¹⁰. Other theories suggest that gas oxidation on the acid-lipid chains of the bacterial wall leads to the death of microorganisms¹¹. After its diffusion inside the cell, ozone gas oxidizes amino acids and nucleic acids, preventing cell replication and leading to denaturation and death of the microorganism³.

Studies have reported some routes of ozone administration, such as auto-hemotherapy, rectal insufflation, hermetic ozone bag, and topical applications through ozonized water and oil¹². There are essentially two ozone metabolizing pathways: 1) ozone reduction by the body's antioxidant systems (ascorbic acid, catalase, glutathione peroxidase, vitamins A and E), leading to the production of reactive oxygen species (ROS) that trigger metabolic pathways in the blood¹; 2) reaction of ozone with hydrophobic compounds in the blood (arachidonic acid, chylomicrons), capable of producing lipid oxidation products (LOPS) and cascade reactions, activating angiogenic, immunological, blood, and neurological factors¹. ROS and LOPS can lead the plasma to a peak oxidative stress event, causing oxy-hemoglobin dissociation and increasing oxygen delivery to ischemic tissues¹. Given the benefits reported in the literature, the aim of this study

was to evaluate the effects of systemic ozone therapy on tissue repair and inflammatory response of induced wounds in the skin of rats.

METHOD

To perform the study, the ethical principles in animal experimentation were followed, recommended by the Brazilian College of Animal Experimentation (COBEA), respecting the Brazilian legislation on experimental animals (Federal Law No. 6,638 -1997) and the research project was submitted for appreciation and approval by the Ethics Committee on the Use of Animals (CEUA) of the Araçatuba School of Dentistry – FOA – UNESP, process no. 02048/2011.

Acclimatization and Study Groups

Twenty-four male Wistar rats, weighing between 250 and 275g, were used. The animals were housed in plastic cages, separated according to the experimental group, containing five rats in each box, in a room with a controlled temperature between 20-22°C, and with relative humidity between 50-52%, with 12-hour light-dark cycles, being fed with normal industrial food (Purina Labina®, Nestle Purina Petcare, Ribeirão Preto, Brazil) and water *ad libitum*.

The rats were randomly divided into two groups, with 12 animals each, as follows: 1) Group C (sham control therapy, with the introduction of the cannula into the rectum, simulating rectal insufflation) and, 2) Group O₃ (test therapy, rectal insufflation of ozone gas (O₃) at a concentration of 50 µg/mL, totaling a volume of 5.0 mL per session).

Animals from both groups started therapies immediately after skin injury. Bio-oxidative therapy (group O₃) or sham (group C) was performed twice a week until the day of the respective euthanasia (7 or 15 days after *baseline*). In each period, six animals from each group were euthanized through anesthetic overdose with 150 mg/Kg of Thiopental (Cristalia, chemical products Farmacêuticos LTDA, Itapira, São Paulo, Brazil).

Wound Induction

The animals' feed was suspended four hours before the surgical procedures, but access to water remained *ad libitum*. Anesthetic procedures were performed by placing the animals in a closed plastic bell jar, with cotton wool moistened with ethyl ether, until the level of anesthesia was reached. The anesthetic level was checked when there was no movement of the head, extremities, or trunk, and disappearance of eyelid reflexes, but with a constant respiratory rate. After anesthesia, all animals underwent the same surgical procedure, which consisted of epilation by manual traction of the back hair, with an extension of 6 cm in length and 4 cm in width, caudally, in an imaginary line to the lower edge of the ears. Next, a circular incision of 1 cm in diameter was made in the center of the epilate area, with a circular biopsy cutting *punch* (Paramount Sterile Dermal Biopsy Punch, Germany), restricted to the dermis and epidermis.

Ozone Therapy

A gas mixture of O₂-O₃ at a concentration of 50 µg/mL of ozone was obtained from a medical ozone generator (Philozon®, Industry and Trade of Ozone Generators, Santa Catarina, Brazil), MedPlus model (Registered at Anvisa 80472910001), produced from medical oxygen with 99.5% purity. The gas mixture was collected using a 5mL siliconized plastic Luer syringe (BD - Becton, Dickinson and Companhia, Juiz de Fora, MG, Brazil) and administered by rectal insufflation, using

a silicone suction cannula, which was inserted 4.0 cm into the rectum of the animal with the aid of lubricating gel¹³.

Macroscopic Evaluation

Macroscopic analysis was performed to verify the size and clinical characteristics of the wound. Thus, after euthanasia, the animals were placed on a surgical board and their wounds were examined with the aid of a magnifying glass with 2.5 times magnification, to verify the presence of crusts, secretions, hypertrophic scars, and evaluation of the size of the residual wound in its longest axis, measured with a PCPN115BR millimeter periodontal probe (Hu-Friedy®, Chicago, USA). The findings were noted on previously prepared forms. The photographic record was carried out using a digital camera with 1.3 approximation, fixed on a tripod for stabilization of the set and standardization. The measurement of the largest diameter was determined and then the area with the lesion was removed with a scalpel blade, no. 15 C, Solidor brand (Bunzl Saúde, Osasco, São Paulo, Brazil), with a 1 cm margin of skin around the lesion. All specimens were fixed in 4% paraformaldehyde solution for 48 hours and sent for laboratory processing.

Histological Evaluation

The skins of the animals were removed and fixed in 4% buffered formalin for further histological analysis. After 48 hours of fixation, the specimens were embedded in paraffin. From then on, the blocks obtained were cut in order to obtain several specimens, four (4) μm in thickness. The histological sections chosen were the central part, representative of the lesion, which were stained with Hematoxylin and Eosin (H&E) and Masson's Trichomium (MT), the latter used for specific collagen staining. The specimens were intended for descriptive histological analysis using conventional light microscopy and histometric analysis. Six slides were obtained from each wound and evaluated for the presence of blood vessels in the healing area, re-epithelialization, collagen proliferation, presence of fibroblasts, and mono and polymorphonuclear leukocytes. Histological analysis was carried out by two previously trained and calibrated examiners, blinded to the study groups, at two different times.

Histological evaluation was performed on the samples stained with H&E and MT under X20, X40, and X100 magnification. Inflammatory exudates, connective tissue, and inflammatory cell density were evaluated in the wound area. Inflammatory cell density was scored according to the scoring system previously used by Ryu et al.¹⁴ The cell density was scored as follows: 0, no inflammation; 1, mild inflammation; 2, moderate inflammation; and 3, intense inflammation. In this scoring system, the inflammatory responses based on the degree of neutrophil, histiocyte and lymphocyte infiltration, ulceration, fibrosis, and granulation tissue were evaluated and scored using a scale of 0–3.

Histometric Evaluation

This analysis was performed using Leica Application Suite 3.8.0 software (Leica Microsystems LTD, Heerburg, Germany). Measurements were taken in the connective tissue region, considering the area of wound contraction. To determine this area of interest, an imaginary linear tracing was initially established, extending from the epithelial tissue to the muscle tissue, in the direction of the remaining adipose tissue. From this delimitation, measurement was performed of the areas of contraction of the connective tissue that projected towards the center of the wound. The measurements were performed in triplicate, with an interval of one week for each evaluation and by two examiners previously trained and blinded to the analysis group.

To obtain panoramic images of the lesions, four to eight photos of the sample were taken, with 4x magnification, with each photo showing at its edge, areas of overlap with the adjacent images. It was

possible to join the images through digital "stitching", using an image analyzer program, by superimposing the coincident pixels.

The trichrome-stained samples were evaluated to determine the epithelial differences between the test and control groups. The total width of the wound area and the amount of new epithelial tissue that proliferated centrally from the wound edges were calculated using a 100-unit ocular grid. The calculated values were compared with each other and scored according to the epithelial grading method previously used by Innes et al.¹⁵, as follows: 0, no re-epithelialization; 1, less than 50% re-epithelialization; 2, more than 50% re-epithelialization; 3, complete re-epithelialization. Table 1 presents the parameters considered for the analyses carried out in the study.

Table 1. Parameters evaluated and their respective scores

Parameters	Scores			
	0	1	2	3
Wound contraction	Absent	Initial (1/3 of initial size)	Medium (2/3 of original size)	Complete (absolute closing)
Re-epithelialization	Absent	Initial (1/3 of initial size)	Medium (2/3 of original size)	Complete (absolute closing)
Edema	Absent	Light	Moderate	Intense
Vessels	Absent	Light	Moderate	Intense
Hemorrhage	Absent	Light	Moderate	Intense
Fibrinopurulent membrane	Absent	Fine	Medium	Wide
Muscle regeneration	Absent	Light	Moderate	Intense
Hair follicle	Absent	Light	Moderate	Intense
Acute inflammation	Absent	Light	Moderate	Intense
Chronic inflammation	Absent	Light	Moderate	Intense
Mixed inflammation	Absent	Light	Moderate	Intense

Statistical Analysis

Statistical analysis was performed using a specific program (BioEstat 5.0, Civil Society Mamirauá / MCT - CNPq, Belém, Brazil), considering the null hypothesis based on the absence of differences between treatment modalities ($\alpha = 5\%$). The unit of analysis was the animal. The joint analysis of the effects of the day (7 and 15) and of the group (control and test) of the numerical variable (surgical area) was performed using the ANOVA test, followed by the Bonferroni test. The variables of the histological evaluation of the categorical data were analyzed by the Kruskal-Wallis test, followed by Tukey. The level of significance used to reject the null hypothesis was 5% ($p < 0.05$).

RESULT

Macroscopic Analysis

The animals in the control group (C) presented a mean residual wound size of 9.0 (± 0.5) mm on the 7th day, while in the treated group (O₃) this was 7.0 (± 0.5) mm. At 15 days, there was a residual wound of 3.0 (± 0.5) mm in group C and complete tissue repair in group O₃.

Histological Analysis

On the 7th day, group C presented connective tissue with few vessels, light hemorrhage, and moderate interstitial edema, in addition to an intense acute inflammatory process in the most coronal portion of the lesion, with a predominance of neutrophils, while in the lower portion there was a characteristic of moderate mixed inflammation, with a predominance of macrophages and lymphocytes. The fibrin-purulent membrane was thick and contaminated. On the 15th day, there was a mild mixed inflammatory process in the lower portion of the tissue, with a predominance of lymphocytes (Figure 1A).

On the 7th day, the O₃ group presented connective tissue with vessels in moderate quantity, light hemorrhage, and moderate interstitial edema. The inflammatory process had a moderate acute character in the most coronal portion of the lesion, with a predominance of neutrophils, while in the lower portion there was a characteristic of moderate mixed inflammation, with a predominance of macrophages and lymphocytes. On the 15th day, there was no inflammatory process, complete muscle regeneration, intense formation of hair follicles, and dense connective tissue (Figure 1A).

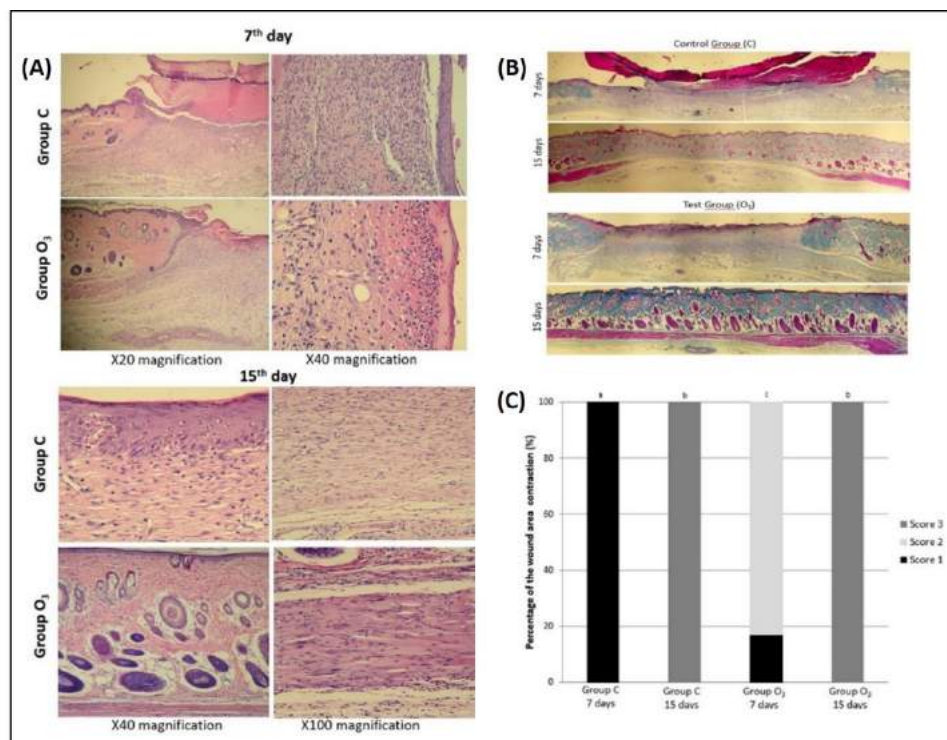


Figure 1. (A) Histological cut of the wound after 7 and 15 days of tissue repair in groups C and O₃, H.E staining (X20, X40 and X100 magnification); (B) Main morphometric findings in the wounds 7 and 15 days post-wound induction, M.T. staining (X4 magnification). The mean wound area was significantly smaller in the treated group (O₃) than in the control group (C) at 7 and 15 days; (C) **Graphic representation of percentage wound area contraction.** The higher the score, the greater the wound contraction. Kruskal-Wallis test (Dunn's test), p-values < .05 were considered statistically significant. means significant difference with the control group. MT: Masson's Trichrome staining.

Histomorphometric Analysis

Figure 1B illustrates that the mean wound area was significantly smaller in the treated group (O₃) than in the control group (C) at 7 and 15 days. The quantitative results regarding tissue aspects in both groups can be seen in Table 2.

Table 2. Median scores (first and third quartiles) of tissue parameters evaluated in the different groups and study periods

	Group C	Group O ₃	P-value
Wound healing			
7 days	1 (1 - 1) ^a	2 (2 - 2) ^a	0.0051
15 days	3 (3 - 3) ^b	3 (3 - 3) ^b	1.000
Re-epithelialization			
7 days	1 (1 - 1) ^a	1.5 (1 - 2) ^a	0.0555
15 days	3 (3 - 3) ^b	3 (3 - 3) ^b	1.000
Edema			
7 days	2 (1 - 2) ^a	1 (0 - 1) ^a	0.0318
15 days	0 (0 - 1) ^b	0 (0 - 0) ^a	0.2948
Vessels			
7 days	1 (1 - 2) ^a	3 (3 - 3) ^a	0.0109
15 days	1 (1 - 1) ^a	0 (0 - 1) ^b	0.05
Hemorrhage			
7 days	2 (1 - 2) ^a	1 (0 - 1) ^a	0.0318
15 days	0 (0 - 0) ^b	0 (0 - 0) ^a	1.000
Fibrinopurulent membrane			
7 days	2 (2 - 2.75) ^a	1 (0.25 - 1.75) ^a	0.1161
15 days	0 (0 - 0.75) ^b	0 (0 - 0) ^a	0.3358
Muscle regeneration			
7 days	1 (1 - 1) ^a	1 (1 - 1.75) ^a	0.3359
15 days	2 (2 - 2) ^b	3 (3 - 3) ^b	0.0013
Hair follicle			
7 days	0 (0 - 0) ^a	0 (0 - 0) ^a	1.000
15 days	2 (2 - 2) ^b	3 (3 - 3) ^b	0.0062

Kruskal-Wallis test followed by Dunn. P<0.05 indicates a statistically significant difference between groups (Group C versus × O₃) in the same period. ^{a,b} Different letters within the column indicate a statistically significant intragroup difference between periods (7 × 15 days).

Both groups (C and O₃) showed good wound healing evolution, with a significant difference between periods (7 × 15 days; P<0.05). Group O₃ demonstrated better healing appearance than group C at seven days (p=0.0051), with no significant difference between groups at 15 days (P>0.05). As wound closure was complete in both groups within 15 days (C and O₃), measurement of wound contraction areas was performed only within 7 days of tissue repair. In this context, it can be seen that the animals in the O₃ group had a higher mean connective tissue contraction area, compared to group C; 1.83 ± 0.4 and 1.0 ± 0.0 respectively. The percentage wound contraction scores in groups C and O₃ are presented in Figure 1C, whereby the higher the score, the greater the wound contraction.

Re-epithelialization improved in groups C and O₃ between the periods (7 × 15 days; P<0.05), with no significant difference between groups in any period (P>0.05). Regarding edema, there was an improvement with a statistical difference between 7 × 15 days for group C (P<0.05), while the O₃ group showed a low level of edema from the beginning of the study, with no difference between periods (P>0.05). The O₃ group presented a higher vessel score at 7 days compared to group C (p=0.0109), with no difference between groups at 15 days (P>0.05). At 7 days, hemorrhage in Group C was significantly greater than in the O₃ group (p=0.0318).

In the initial periods of the tissue repair process (7 days), the C group demonstrated a greater tendency to present a thicker fibrinopurulent membrane compared to the O₃ group, but with no statistical difference (P>0.05). At 15 days, the O₃ group showed a significant increase in muscle regeneration (p=0.0013) and in the presence of hair follicles (p=0.0062), compared to group C.

The tissue inflammatory aspects can be found in Table 3. Group C presented a significant reduction in acute inflammation and a significant increase in chronic inflammation over the experimental period (7 × 15 days; p<0.05). The O₃ group presented significantly mixed

inflammation ($p=0.0021$) on the 7th day, which significantly reduced to a total absence of inflammation during the experimental period (7×15 days).

Table 3. Median scores (first and third quartiles) of inflammatory parameters in different groups and periods

	Group C	Group O ₃	P-value
Acute inflammation			
<i>Superficial tissue</i>			
7 days	3 (3 – 3) ^a	0 (0 – 0) ^a	0.0053
15 days	0 (0 – 0) ^b	0 (0 – 0) ^a	1.000
<i>Deep tissue</i>			
7 days	0 (0 – 0) ^a	0 (0 – 0) ^a	1.000
15 days	0 (0 – 0) ^a	0 (0 – 0) ^a	1.000
Chronic inflammation			
<i>Superficial tissue</i>			
7 days	0 (0 – 0) ^a	0 (0 – 0) ^a	1.000
15 days	1 (1 – 1) ^b	0 (0 – 0) ^a	0.0053
<i>Deep tissue</i>			
7 days	2 (2 – 2) ^a	0 (0 – 0) ^a	0.0053
15 days	0 (0 – 0) ^b	0 (0 – 0) ^a	1.000
Mixed inflammation			
<i>Superficial tissue</i>			
7 days	0 (0 – 0) ^a	0 (0 – 0) ^a	1.000
15 days	0 (0 – 0) ^a	0 (0 – 0) ^a	1.000
<i>Deep tissue</i>			
7 days	0 (0 – 0) ^a	2 (2 – 2) ^a	0.0021
15 days	0 (0 – 0) ^a	0 (0 – 0) ^b	1.000

Kruskal-Wallis test followed by Dunn. $P < 0.05$ indicates a statistically significant difference between groups in the same period.

^{a,b} Different letters within the column indicate a statistically significant intragroup difference between periods (7×15 days).

Acute inflammation in Group C was statistically higher than in Group O₃ ($p=0.0053$) at the beginning of the experimental period (7 days). At the end of the experimental period (15 days), chronic inflammation was significantly higher in group C compared to group O₃ in both superficial and deep tissues ($p < 0.05$).

DISCUSSION

The removal of a skin fragment induces the formation of a continuity solution that is filled with fibrin, clot, and inflammatory exudate, forming the crust that covers the wound. The repair starts with the formation of the clot, followed by the release of pro-inflammatory mediators, developing an acute inflammatory reaction⁹. At the beginning of the inflammatory phase of the healing process, there is an increase in vascular permeability, extravasation of plasma, red blood cells, platelets, and leukocytes, especially neutrophils, monocytes, and macrophages.

In the current study, interesting differences were found regarding the course of the repair process. While in the control (group C), characteristics of intense acute inflammatory response, necrotic coagulation tissue, and infected areas were verified on the 7th. day, in the test group (group O₃), the inflammatory process was at a more advanced stage (mixed), without infection. Our findings are in agreement with some authors who verified that wounds on the back of rats treated with ozone therapy presented mature granulation epithelial tissue compared to their respective controls on the

seventh day¹⁶, as well as a decrease in healing time¹⁷. Some authors also found a higher rate of epithelialization and granulation tissue with a lower mean number of neutrophils, in addition to greater dermal cellularity and intense collagen deposition compared to the control group¹⁸.

The increase in collagen fibers until the 7th day promotes a decrease in blood flow, consequently reducing the constituents of the granulation tissue, causing it to change its structure, to become a typical connective tissue. In the present study, wound contraction in the O₃ group (1.83 ± 0.40) showed a statistically higher mean over the 7-day period compared to group C (1.0 ± 0.0), but with no significant difference between groups at 15 days. On the other hand, Soares et al.¹⁸ found that the mean wound area was significantly smaller in the group treated with ozone at both 7 and 14 days. Some studies report that this fact is due to ozone therapy stimulating tissue neovascularization and, consequently, inducing an increase in tissue oxygenation, stimulating cellular and functional differentiation of myofibroblasts and tissue repair¹⁹. This fact may justify the occurrence of complete muscle regeneration on the 15th day in the group treated with ozone (O₃ group) in our study.

Considering studies with the use of ozone, it is believed that under different forms of application, ozone enabled a greater increase in the quantity of polymorphonuclear leukocytes, greater protein synthesis¹⁸, and greater release of growth factors for the construction of the extracellular matrix, such as transforming growth factor 1 (TGF1), vascular endothelial growth factor (VEGF), and immunoreactivity to fibroblast growth factor 2, which aid in the tissue repair process of dermal wounds¹⁸. Ozone is able to increase the concentration of red blood cells and hemoglobin levels, improving circulation and oxygenation of peripheral tissues, and increasing diapedesis and phagocytosis². These facts may explain the acceleration of the tissue repair process observed in the O₃ group in the period of 7 days, characterized by greater contraction of the wound, mixed inflammatory infiltrate, and intense neovascularization.

The justification for access via rectal insufflation is indicated because it is an innocuous technique, without any side effects or damage to the animal or human being¹³. Although the rectal route for the application of the ozone gas mixture is empirical, it is considered an easy, practical, and non-toxic technique. Ozone gas doses through the rectal insufflation technique promotes rapid and transient oxidative preconditioning, capable of developing a protective effect on the liver, preserving the mitochondrial function of cells, controlling the release of inflammatory mediators, and preventing greater cell and tissue damage¹³. Considering this protocol, the present study confirmed immunomodulatory properties in the inflammatory response, in addition to repairing and regenerative properties, as greater wound contraction was found in the initial period of the repair process (7th day), suggesting a decrease in the time of wound repair and greater tissue quality with dense and mature connective tissue on the 15th day, along with complete regeneration of muscle tissue. On the other hand, some authors²⁰ used ozone gas topically in the palatal gingiva of pigs for periods of 3, 7, and 10 days and found no differences between the test and control groups in terms of collagen fibers, epithelial formation, and inflammation score, however greater expression of VEGF was observed in the group treated with ozone compared to the test groups in the initial periods of 3 and 7 days, demonstrating that topically applied ozone therapy can be effective in the early stages of oral healing.

Thus, it was found that bio-oxidative therapy with ozone gas offers additional benefits to tissue repair processes. The clinical application of this therapy is suggested as a treatment option for patients with problems of immunity, coagulation, repair, and/or healing.

CONCLUSION

It can be concluded that systemic ozone therapy was able to improve wound healing in the initial period, reducing the characteristics of acute inflammation, in addition to accelerating

muscle regeneration and skin appendages. Thus, it can be stated that bio-oxidative therapy with ozone gas had a biomodulatory effect, increasing tissue repair and regeneration in rat skin.

REFERENCES

1. Bocci V, Aldinucci C. Biochemical modifications induced in human blood by oxygenation-ozonation. *J Biochem Mol Toxicol*. 2006;20(3):133-8. <http://dx.doi.org/10.1002/jbt.20124>. PMID:16788956.
2. Bocci V. Ozone as Janus: this controversial gas can be either toxic or medically useful. *Mediators Inflamm*. 2004 Feb;13(1):3-11. <http://dx.doi.org/10.1080/0962935062000197083>. PMID:15203558.
3. Emerson MA, Sproul OJ, Buck CE. Ozone inactivation of cell-associated viruses. *Appl Environ Microbiol*. 1982 Mar;43(3):603-8. <http://dx.doi.org/10.1128/aem.43.3.603-608.1982>. PMID:6280611.
4. López EG, Martínez AR, Ruiz AOB, García LOR. La ozonoterapia en el tratamiento de la estomatitis subprótesis. *Rev Cubana Estomatol [Internet]*. 2003 Ago [cited 2021 Sep 3];40(2). Available from: http://scielo.sld.cu/scielo.php?script=sci_arttext&pid=S003475072003000200004&lng=es
5. Estrela C, Estrela CRA, Decurcio DA, Silva JA, Bammann LL. Antimicrobial potential of ozone in an ultrasonic cleaning system against *Staphylococcus aureus*. *Braz Dent J*. 2006;17(2):134-8. <http://dx.doi.org/10.1590/S0103-64402006000200010>. PMID:16924341.
6. Khan SA, Suh Y, Patel S, Kaitlyn R, Gandhi J, Joshi G, et al. Clinical utility of ozone therapy in dental and oral medicine. *Med Gas Res*. 2019 Jul-Sep;9(3):163-7. <http://dx.doi.org/10.4103/2045-9912.266997>. PMID:31552882.
7. Agrillo A, Ungari C, Filiaci F, Priore P, Iannetti G. Ozone therapy in the treatment of avascular bisphosphonate-related jaw osteonecrosis. *J Craniofac Surg*. 2007 Sep;18(5):1071-5. <http://dx.doi.org/10.1097/scs.0b013e31857261f>. PMID:17912085.
8. Bocci V. Biological and clinical effects of ozone. Has ozone therapy a future in medicine? *Br J Biomed Sci*. 1999;56(4):270-9. PMID:10795372.
9. Kim HS, Noh SU, Han YW, Kim KM, Kang H, Kim HO, et al. Therapeutic effects of topical application of ozone on acute cutaneous wound healing. *J Korean Med Sci*. 2009 Jun;24(3):368-74. <http://dx.doi.org/10.3346/jkms.2009.24.3.368>. PMID:19543419.
10. Brink CB, Pretorius A, van Niekerk BPJ, Oliver DW, Venter DP. Studies on cellular resilience and adaptation following acute and repetitive exposure to ozone in cultured human epithelial (HeLa) cells. *Redox Rep*. 2008;13(2):87-100. <http://dx.doi.org/10.1179/135100008X259187>. PMID:18339251.
11. Dähnhardt JE, Jaeggi T, Lussi A. Treating open carious lesions in anxious children with ozone. A prospective controlled clinical study. *Am J Dent*. 2006 Oct;19(5):267-70. PMID:17073201.
12. Cruz Guerra O, Menéndez Cepero S, Martínez Jordan ME, Clavera Vázquez T. Aplicación de la ozonoterapia en el tratamiento de la alveolitis. *Rev Cubana Estomatol [Internet]*. 1997 Jun [cited 2021 Sep 3];34(1):21-4. Available from: http://scielo.sld.cu/scielo.php?script=sci_arttext&pid=S0034-75071997000100004&lng=es
13. Fernández OSL, Ajamieh HH, Berlanga J, Menéndez S, Viebahn-Hänsler R, Re L, et al. Ozone oxidative preconditioning is mediated by A1 adenosine receptors in a rat model of liver ischemia/ reperfusion. *Transpl Int*. 2008 Feb;21(1):39-48. PMID:17927680.
14. Ryu S-W, Lee S-H, Yoon H-J. A comparative histological and immunohistochemical study of wound healing following incision with a scalpel, CO2 laser or Er,Cr:YSGG laser in the Guinea pig oral mucosa. *Acta Odontol Scand*. 2012 Dec;70(6):448-54. <http://dx.doi.org/10.3109/00016357.2011.635598>. PMID:22149727.
15. Innes ME, Umraw N, Fish JS, Gomez M, Cartotto RC. The use of silver coated dressings on donor site wounds: a prospective, controlled matched pair study. *Burns*. 2001 Sep;27(6):621-7. [http://dx.doi.org/10.1016/S0305-4179\(01\)00015-8](http://dx.doi.org/10.1016/S0305-4179(01)00015-8). PMID:11525858.

16. Rodrigues KL, Cardoso CC, Caputo LR, Carvalho JCT, Fiorini JE, Schneedorf JM. Cicatrizing and antimicrobial properties of an ozonised oil from sunflower seeds. *Inflammopharmacology*. 2004;12(3):261-70. <http://dx.doi.org/10.1163/1568560042342275>. PMID:15527550.
17. Valacchi G, Lim Y, Belmonte G, Miracco C, Zanardi I, Bocci V, et al. Ozonated sesame oil enhances cutaneous wound healing in SKH1 mice. *Wound Repair Regen*. 2011 Jan-Feb;19(1):107-15. <http://dx.doi.org/10.1111/j.1524-475X.2010.00649.x>. PMID:21134039.
18. Soares CD, Morais TML, Araújo RMFG, Meyer PF, Oliveira EAF, Silva RMV, et al. Effects of subcutaneous injection of ozone during wound healing in rats. *Growth Factors*. 2019 Apr;37(1-2):95-103. <http://dx.doi.org/10.1080/08977194.2019.1643339>. PMID:31339390.
19. Clavo B, Pérez JL, López L, Suárez G, Lloret M, Rodríguez V, et al. Effect of ozone therapy on muscle oxygenation. *J Altern Complement Med*. 2003 Apr;9(2):251-6. <http://dx.doi.org/10.1089/10755530360623365>. PMID:12804078.
20. Eroglu ZT, Kurtis B, Altug HA, Sahin S, Tuter G, Baris E. Effect of topical ozonotherapy on gingival wound healing in pigs: histological and immuno-histochemical analysis. *J Appl Oral Sci*. 2018 Dec;27:e20180015. <http://dx.doi.org/10.1590/1678-7757-2018-0015>. PMID:30540068.

CONFLICTS OF INTERESTS

The authors declare no conflicts of interest.

*CORRESPONDING AUTHOR

Elizangela Cruvinel Zuza, UFF – Universidade Federal Fluminense, Instituto de Saúde de Nova Friburgo, Programa de Pós-Graduação em Odontologia, Rua Dr. Silvio Henrique Braune, 22, Centro, 28625-650 Nova Friburgo, RJ, Brasil, e-mail: elizangelazuza@id.uff.br

Received: September 3, 2021

Accepted: September 21, 2021